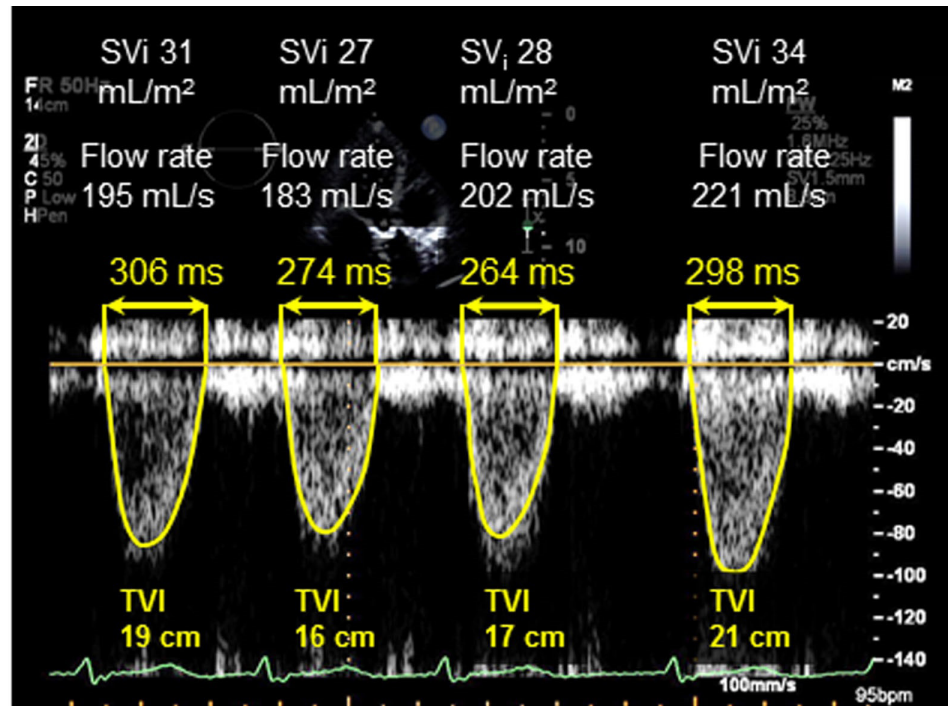
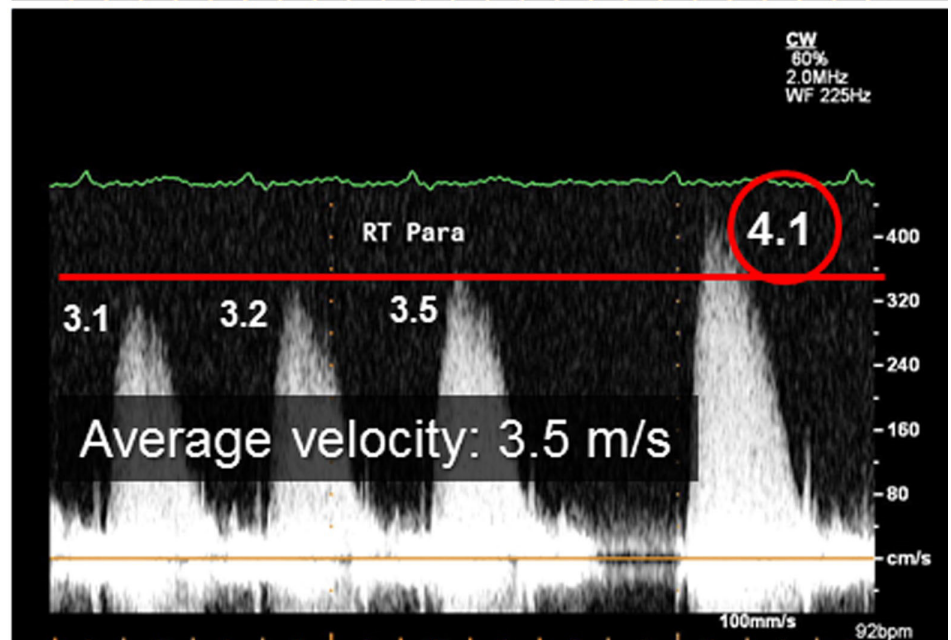


Doppler signals during echocardiogram

LVOT signals



Aortic valve signals



Example of variable cycle lengths and variable consecutive left ventricular outflow tract (LVOT) pulsed-wave and aortic valve continuous-wave Doppler signals in a patient with low-gradient aortic stenosis in atrial fibrillation (AF LGAS) during the echocardiogram. Note the variable indexed stroke volumes (SVi), LVOT flow rates, and transaortic valve peak velocities and mean gradients. For the average of 5 consecutive beats to be at 4 meters per second (m/s) or greater, the preceding or next beat would have to be at least 6.1 m/s. TVI indicates time-velocity integral.