

Endoscopic Transnasal Surgical Technique for Pituitary Tumors

INSIDE THIS ISSUE

3 Primary Aldosteronism: The Role of Adrenal Venous Sampling

5 Laparoscopic Adrenalectomy

Since the 1970s, the standard surgical approach for resection of most pituitary tumors has been the transsphenoidal technique. In the mid 1990s, Mayo Clinic surgeons began using the nasal endoscope in a modification of the standard surgical approach. This new endoscopic transnasal technique decreased operative time, length of hospital stay, and patient discomfort, without compromising surgical success.

Sublabial Transseptal Approach

John L. Atkinson, MD, of the Department of Neurosurgery at Mayo Clinic in Rochester, says: "The sublabial transseptal approach had been the standard procedure for resection of pituitary tumors at Mayo Clinic since the 1970s. This approach to the sphenoid sinus involves making a sublabial incision for access to the nasal cavity and then removing the nasal septum [Figure 1]. The sphenoid sinus is entered, allowing access to the sella turcica. After resection of the tumor, the nasal septum is replaced, requiring nasal packing postoperatively."

Endoscopic Transnasal Approach

Dr Atkinson explains: "The endoscopic transnasal technique requires no external incision. The nasal endoscope is advanced through a nostril to the anterior wall of the sphenoid sinus [Figure 2]. The sphenoid sinus ostium is enlarged, and the posterior portion of the vomer is removed, allowing access to the sphenoid sinus. After placement of a self-retaining nasal speculum, the sella turcica is entered, and the neurosurgical portion of the procedure is undertaken as with the sublabial transseptal approach. After resection of the tumor, the nasal speculum is withdrawn, the nasal septum is adjusted to midline if necessary, and a mustache nasal dressing is applied."

Endoscopic Transnasal Approach vs Sublabial Transseptal Approach

The similarities and differences between the 2 techniques are summarized in the Table. Dr Atkinson notes: "The main difference from the surgeon's standpoint is that with the endoscopic transnasal approach the surgical field is smaller and is angled approximately 10° off center [Figure 2]. The disadvantages that these factors present for the surgeon can be overcome with experience. For the patient, the absence of the sublabial incision eliminates the possibility of postoperative lip numbness. Also, leaving the nasal septum intact decreases postoperative discomfort from nasal packs and reduces the chance of complications related to manipulation of the nasal septum."

A retrospective case-controlled analysis of the initial experience at Mayo Clinic with the endoscopic transnasal technique for resection of nonfunctioning pituitary macroadenomas was published in 1999. This study compared the operative outcomes of patients who had the standard sublabial transseptal procedure with the outcomes of patients who had the endoscopic procedure during the first 3 years after it was introduced. The results showed no differences in completeness

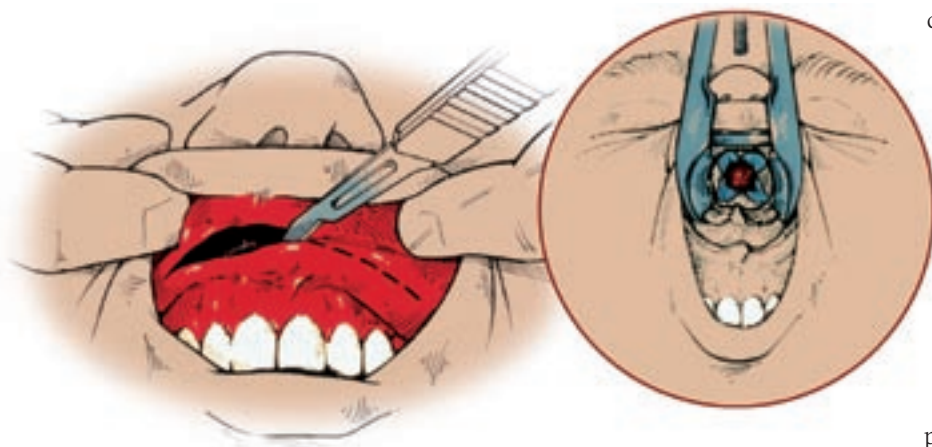


Figure 1. Sublabial transseptal surgical approach. A sublabial incision is made to access the nasal cavity (left panel) for removal of the nasal septum. The sella turcica is accessed through the sphenoid sinus (right panel).

Table. Endoscopic Transnasal Approach Compared With Standard Sublabial Transseptal Approach

Endoscopic Transnasal	Sublabial Transseptal
No external incision	Sublabial incision
Nasal septum intact	Nasal septum removed and replaced
No postoperative nasal packing	Postoperative nasal packing for 3-5 d
Use of operating microscope	Use of operating microscope
Smaller operating field	Larger operating field
Field 10° off center	Field at 90°
Endoscopic visualization	Field at 90°

of tumor resection, change in visual field defects, or alterations in pituitary function between the 2 groups. Operative time, anesthesia time, and length of hospital stay were less in the endoscopic transnasal group.

A subsequent case-controlled analysis of the experience at Mayo Clinic with the endoscopic transnasal technique for resection of corticotropin-secreting pituitary microadenomas was published in 2008. This study compared the operative outcomes of patients who had the standard sublabial transseptal procedure with the outcomes of patients who had the endoscopic procedure. The results showed no differences in Cushing's syndrome cure rates or in complications between



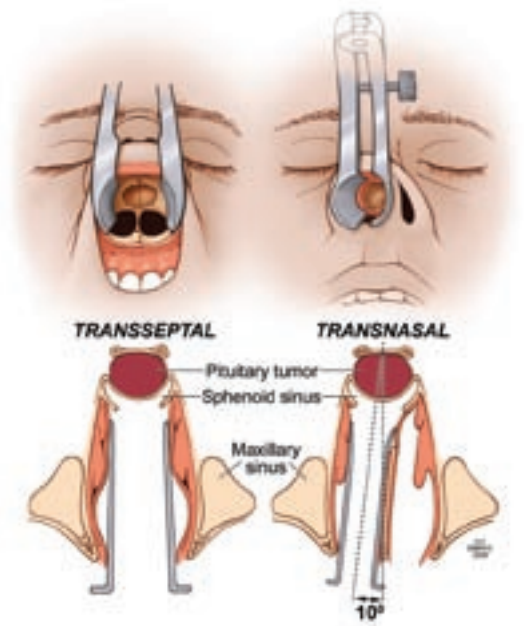
John L. Atkinson, MD, and Charles F. Abboud, MD

the 2 groups. Anesthesia time, blood loss, and length of hospital stay were less in the endoscopic transnasal group.

Perioperative Management

Charles F. Abboud, MD, of the Division of Endocrinology, Diabetes, Metabolism, and Nutrition at Mayo Clinic in Rochester, says: "The endoscopic transnasal approach has now become the standard procedure for removal of functioning and nonfunctioning pituitary adenomas and other sellar masses. Currently, Mayo Clinic neurosurgeons perform approximately 120 transsphenoidal procedures per year. Patients without medical or surgical complications (about 90%) are typically dismissed the morning of the day after surgery and are seen as outpatients by the endocrinologist that afternoon. Any immediate postoperative hormonal deficiencies are treated, and a plan to assess for late postoperative hormonal and surgical complications is developed."

Figure 2. Surgical field for endoscopic transnasal surgery. The surgical field for this procedure (right, top and bottom panels) is smaller than that for the sublabial transseptal procedure (left, top and bottom panels) and is angled approximately 10° off center. Used with permission from Sheehan MT, Atkinson JL, Kasperbauer JL, Erickson BJ, Nippoldt TB. Preliminary comparison of the endoscopic transnasal vs the sublabial transseptal approach for clinically nonfunctioning pituitary macroadenomas. *Mayo Clin Proc.* 1999 Jul;74(7):661-70.



Primary Aldosteronism: The Role of Adrenal Venous Sampling

The triad of hypertension, hypokalemia, and an aldosterone-producing adenoma (APA) of the adrenal gland was first reported by Conn in 1955. The hypertension and hypokalemia in Conn's first patient were cured by removal of an adrenal adenoma. William F. Young, Jr, MD, of the Division of Endocrinology, Diabetes, Metabolism, and Nutrition at Mayo Clinic in Rochester, says: "However, over the past 54 years, 3 facts have become clear. First, primary aldosteronism (PA) is more common than previously thought and it affects between 5% and 10% of all patients with hypertension. Second, most patients with PA are normokalemic. Third, PA has more than 1 cause and most patients with PA have bilateral idiopathic hyperaldosteronism (IHA). Unilateral adrenalectomy in patients with APA results in normalization of hypokalemia in all patients, normalization of blood pressure in at least a third of patients, and mitigation of hypertension in nearly all patients. Whereas, in patients with IHA, a unilateral or bilateral adrenalectomy seldom corrects hypertension. Patients with IHA should be treated not surgically but medically with a mineralocorticoid-receptor antagonist. Therefore, determining the subtype of PA (APA versus IHA) is critical in directing treatment."

In 1967, selective adrenal venous sampling (AVS) for aldosterone was first proposed as a test to distinguish between APA and IHA. However, it is an invasive and difficult technique (the right adrenal vein is small and may be difficult to identify, to cannulate, and to withdraw blood from); both adrenal veins must be sampled for meaningful comparison. When body computed tomography (CT) became available in the late 1970s, it was thought to be a good test to distinguish among the subtypes of PA. Dr Young notes: "However, because of the prevalence of nonfunctioning cortical

adenomas, hormonal hyperfunction cannot be inferred from simply the presence of an adrenal nodule. A patient with IHA may be thought to have an APA because an adrenal nodule was detected on CT—a finding that may be due to the age-related occurrence of nonfunctioning

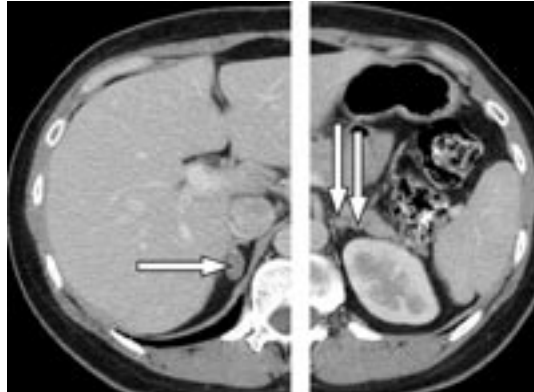


Figure 1. Adrenal computed tomographic scan of a 37-year-old woman with poorly controlled hypertension despite taking 3 antihypertensive drugs. The scan shows an 18-mm right adrenal nodule (arrow, left panel) and 2 left adrenal nodules of 7 mm and 4 mm (arrows, right panel). Adrenal venous sampling lateralized the aldosterone secretion to the right adrenal gland. A cortical adenoma (20 mm × 17 mm × 12 mm) was found at laparoscopic right adrenalectomy. The patient's postoperative plasma aldosterone concentration was low, and her blood pressure was normal without the aid of antihypertensive medications at 18 months after surgery.



William F. Young, Jr, MD, and Anthony W. Stanson, MD

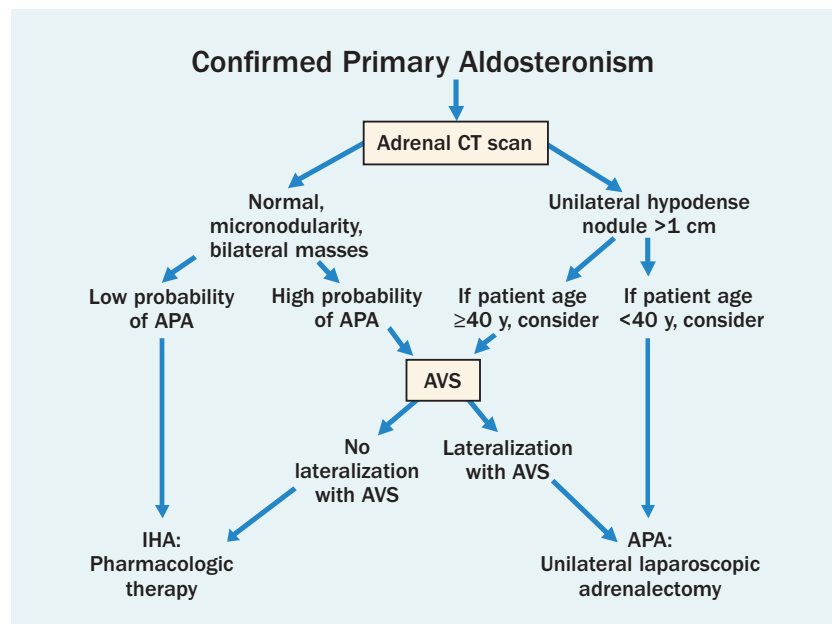


Figure 2. An algorithmic approach to subtype evaluation of a patient with primary aldosteronism. APA, aldosterone-producing adenoma; AVS, adrenal venous sampling; CT, computed tomographic; IHA, idiopathic hyperaldosteronism.

Table. Results of Bilateral Adrenal Venous Sampling (AVS) in the Patient With Primary Aldosteronism Who Had a Computed Tomographic Scan (Figure 1) and AVS Radiographs (Figure 3).

The cortisol concentrations from the adrenal veins and inferior vena cava are used to confirm successful catheterization; the adrenal vein cortisol-to-inferior vena cava cortisol ratio is typically more than 10:1 when the protocol for continuous cosyntropin infusion is followed. Dividing the plasma aldosterone concentrations (PACs) of the right and left adrenal veins by the respective cortisol concentrations corrects for the dilutional effect of blood from the inferior phrenic vein flowing into the left adrenal vein; these quotients are termed cortisol-corrected aldosterone ratios. In patients with aldosterone-producing adenoma (APA), the mean cortisol-corrected aldosterone ratio (APA-side PAC/cortisol concentration-to-normal adrenal PAC/cortisol concentration ratio) is 18:1. A cutoff for the cortisol-corrected aldosterone ratio from high side to low side of more than 4:1 is used to indicate unilateral aldosterone excess. The lateralization ratio in this patient is 20.5:1 and is consistent with a right adrenal APA.

Vein	Aldosterone (A), ng/dL	Cortisol (C), µg/dL	A:C ratio	Aldosterone ratio*
Right adrenal vein	8,096	1,520	5.33	20.5
Left adrenal vein	225	870	0.26	
Inferior vena cava	41	22	1.86	

*Right adrenal vein A:C ratio divided by left adrenal vein A:C ratio.

terone ratio (APA-side PAC/cortisol concentration-to-normal adrenal PAC/cortisol concentration ratio) is 18:1. A cutoff for the cortisol-corrected aldosterone ratio from high side to low side of more than 4:1 is used to indicate unilateral aldosterone excess. The lateralization ratio in this patient is 20.5:1 and is consistent with a right adrenal APA.

adrenal cortical nodules. Yet, APAs that are 3 or 4 mm in diameter may escape detection on CT or a patient with a unilateral APA may have bilateral adrenal nodules on CT—one that is nonfunctional and one that is hypersecreting aldosterone [Figure 1]. An approach to these clinical dilemmas is shown in the algorithm [Figure 2], which outlines that AVS is not needed in all patients with PA. Because adrenal ‘incidentalomas’ are uncommon in young patients, when a solitary unilateral macronodule (>1 cm) and a normal contralateral adrenal are found on CT in a patient with PA, unilateral adrenalectomy is reasonable to consider. In addition, many patients prefer pharmacologic therapy and therefore AVS is not needed. With this approach, AVS is performed in approxi-

mately 20% of Mayo Clinic patients with PA.”

Patients with an APA have more severe hypertension, more frequent hypokalemia, and higher plasma (>25 ng/dL) and urinary (>30 µg/24 h) levels of aldosterone and are younger than those with IHA. Patients with these findings are considered to have a “high probability” of APA (see Figure 2). However, these findings are not absolute predictors of unilateral, versus bilateral, adrenal disease.

Dr Young explains: “Between September 1990 and October 2003, we prospectively selected 203 patients with PA (mean age, 53 years; range, 17–80 years; 163 men) for AVS on the basis of degree of aldosterone excess, age, desire for surgical treatment, and findings on CT. Both adrenal veins were catheterized in 194 patients (96%). Among these patients, the 110 patients (57%) with unilateral aldosterone hypersecretion included 24 of 58 patients (41%) with normal adrenal findings on CT; 24 of 47 (51%) with unilateral micronodule (≤10 mm) apparent on CT (7 had unilateral aldosterone hypersecretion from the contralateral adrenal), 21 of 32 (66%) with unilateral macronodule (>10 mm) apparent on CT (1 had unilateral aldosterone hypersecretion from the contralateral adrenal), 16 of 33 (48%) with bilateral micronodules, and 2 of 6 (33%) with bilateral macronodules. On the basis of computed tomographic findings alone, 42 patients (22%) would have been incorrectly excluded as candidates for adrenalectomy, and, more importantly, 48 (25%) might have had unnecessary or inappropriate adrenalectomy. Therefore, AVS is an essential diagnostic step in most patients with PA, to distinguish between unilateral and bilateral adrenal

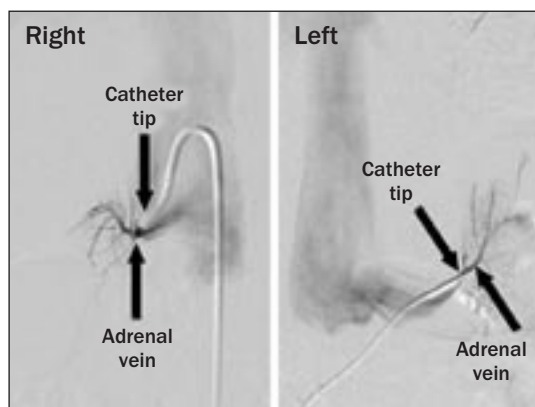


Figure 3. Images of adrenal venous sampling performed in the patient with primary aldosteronism whose computed tomographic scan is shown in Figure 1. Radiographs show catheters placed in the right and left adrenal veins.

aldosterone hypersecretion (see Figure 2).

Anthony W. Stanson, MD, of the Department of Radiology at Mayo Clinic in Rochester, says: "We have now performed AVS in more than 400 patients. The adrenal veins are sequentially catheterized through the percutaneous femoral vein approach under fluoroscopic guidance, and correct catheter tip location is confirmed with injection of a small amount of contrast medium [Figure 3]. Blood is obtained by gentle aspiration from both adrenal veins. Successful catheterization may require an array of catheter configurations, either available from manufacturers or custom-made with steam-shaping during the procedure to facilitate access to the adrenal veins. The placement of side holes very close to the catheter tip may enhance

the progress of the blood draw. At centers with experience with AVS, the complication rate is 2.5% or less. Complications can include symptomatic groin hematoma, adrenal hemorrhage, and dissection of an adrenal vein. Aldosterone and cortisol concentrations are measured in the blood from all 3 sites (right adrenal vein, left adrenal vein, and inferior vena cava) [Table]. All of the blood samples should be assayed at 1:1, 1:10, and 1:50 dilutions—absolute values are mandatory. Accurate laboratory assays for cortisol and aldosterone are keys to successful interpretation of the AVS data."

Dr Young concludes: "For patients with PA who want to pursue the surgical treatment option, AVS is the key diagnostic step."

Laparoscopic Adrenalectomy

For many years, open posterior adrenalectomy with resection of the 12th rib was the most common and accepted surgical approach for most functioning and nonfunctioning, benign primary adrenal neoplasms. This operative approach had clear-cut advantages over standard laparotomy in terms of reduced pulmonary complications, more rapid return of gastrointestinal tract function, less blood loss, and more rapid recovery. Geoffrey B. Thompson, MD, of the Department of Surgery at Mayo Clinic in Rochester, explains: "However, with long-term follow-up, it became apparent that more than half of patients who underwent open posterior adrenalectomy had some degree of long-term

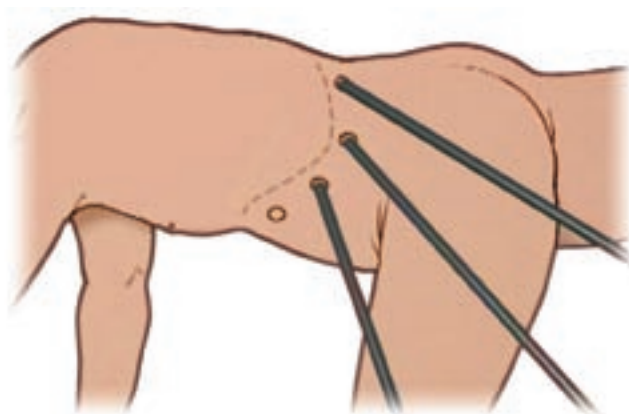
incision-related morbidity, including flank pain, paresthesias, and loss of muscle tone characterized by a bulging flank caused by subcostal nerve injury. With the advent of minimally invasive surgery, the transperitoneal approach to laparoscopic adrenalectomy [Figures 1 and 2] was developed to manage both functioning and nonfunctioning adrenal neoplasms. This innovation stimulated worldwide interest, resulting in a procedure that has become the standard for most functioning and nonfunctioning, benign adrenal neoplasms smaller than 8 cm."

Between 1992 and 2006, Mayo Clinic endocrine surgeons performed 599 laparoscopic adrenalectomies in 523 patients (45% men;



Geoffrey B. Thompson, MD

Figure 1. The lateral transperitoneal approach to laparoscopic adrenalectomy. The lateral decubitus position of the patient and the medial rotation of the viscera allow gravity to keep the liver, bowel, and spleen away from the surgical field. The shown skin incisions are 1 cm in length and 2 cm below and parallel to the costal margin. Four 10-mm trocar ports are established, the laparoscope is placed through the most anterior trocar, and the working instruments are placed through the other port sites.



55% women). Of the procedures 94% were successfully completed laparoscopically, and of these adrenalectomies 44% were right-sided, 41% were left-sided, and 15% were bilateral. Dr Thompson adds: "Functioning adrenal tumors comprised 83% of this operative experience (primary aldosteronism, 33%; Cushing's syndrome, 25%; and pheochromocytoma, 25%). Mean operating time was 162 minutes; length of hospital stay, 3 days; and time before return to normal activities, 10 to 14 days. Among the patients, 93% had no perioperative complications, 5% had transient procedure-related complications, and 2% had perioperative complications unrelated to the technical aspects of the procedure. No perioperative deaths occurred. The cure rates for primary aldosteronism, Cushing's syndrome, and pheochromocytoma have been identical in both open- and laparoscopic-approach cohorts at Mayo Clinic."

Between 1995 and 2006, bilateral laparoscopic adrenalectomy for Cushing's syndrome was attempted in 68 patients with corticotropin-dependent (ACTH-dependent) Cushing's syndrome (26 had ectopic ACTH-dependent Cushing's syndrome and 42 had persistent pituitary-dependent Cushing's syndrome after a pituitary surgery). Bilateral laparoscopic adrenalectomy was successfully completed in 59 patients (87%); conversion to open adrenalectomy was required in 9 patients (13%). Intraoperative complications occurred in 3 patients (4%) (2 had the laparoscopic approach and 1 had the open approach), and nonoperative complications occurred in 11 patients (16%) (8 had the laparoscopic approach and 3 had the open approach). There were no perioperative deaths. Median length of hospital stay was 5.5 days (range, 3-28 days) and 11.9 days (range, 4-29 days) for the groups with laparoscopic and open procedures, respectively. Dr Thompson adds: "Of patients with follow-up data available, all achieved biochemical resolution and at least partial clinical resolution of signs and symptoms associated with hypercortisolism. Resolution of hypertension, diabetes mellitus, and obesity was achieved in 64%, 29%, and 35% of patients who had those diagnoses before the surgery, respectively. No residual cortisol secretion was identified in any of these patients."

Mayo Clinic endocrine surgeons have also used laparoscopic adrenalectomy in the management of selected cases of congenital adrenal hyperplasia (CAH). Dr Thompson comments: "This approach is a reasonable alternative for selected patients with severe CAH, especially those who are known 'salt wasters' and are already taking mineralocorticoids. Bilateral

laparoscopic adrenalectomy eliminates the need for supraphysiologic doses of glucocorticoids, as well as the need for androgen receptor-blocking agents."

Laparoscopic adrenalectomy has also been used at Mayo Clinic to manage pheochromocytomas in patients with such familial disorders as von Hippel-Lindau syndrome and neurofibromatosis type 1. Cortical-sparing adrenalectomy is possible laparoscopically with the aid of laparoscopic ultrasonography and the use of the ultrasonic dissecting shears. In most instances, this treatment has allowed patients to avoid exogenous corticosteroid dependency. Because of the availability of laparoscopic adrenalectomy, Mayo Clinic surgeons have also been strong advocates of unilateral adrenalectomy in patients with a diagnosis of multiple endocrine neoplasia type 2 (MEN 2) but without obvious bilateral disease. Dr Thompson cautions: "Whether cortical-sparing adrenalectomy is appropriate in patients with MEN 2 remains to be determined, given theoretical concerns over transecting an adrenal medulla with medullary hyperplasia."

Dr Thompson concludes: "Laparoscopic adrenalectomy has become the standard surgical approach at experienced endocrine centers for most patients with small benign, functioning and nonfunctioning adrenal neoplasms. Adrenocortical carcinomas have been considered a contraindication to laparoscopic adrenalectomy at Mayo Clinic, and an open anterior approach is favored for obvious cancers. An open approach facilitates dissection of contiguous structures to better sample lymph nodes and to better avoid tumor spillage with larger tumors."

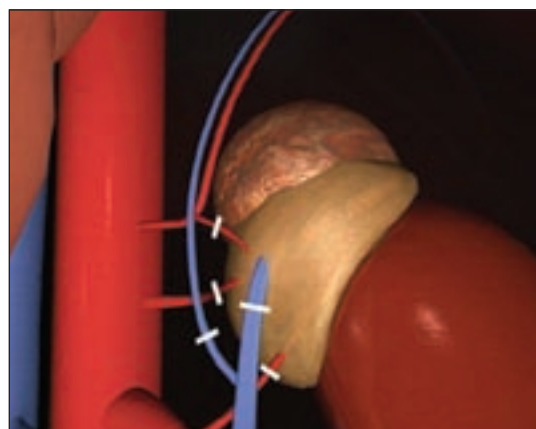



Figure 2. Access to adrenal vessels during laparoscopic adrenalectomy. The main adrenal vein is identified, clipped, and transected. The remaining adrenal vessels are also clipped and transected. The adrenal gland and tumor are resected, placed in a retrieval pouch, and pulled up through the port site.



David R. Farley, MD, was President of the Minnesota Surgical Society in 2008. Robert D. Tiegs, MD, received the 2008 Department of Internal Medicine Laureate Award. Helen Karakelides, MD, received the Teacher of the Year Award for 2008 from the Department of Internal Medicine, Mayo Fellows Association, Mayo Clinic Rochester.



Sundeep Khosla, MD, received the Department of Medicine 2008 Outstanding Investigator Award and also received the Dr Francis Chucker and Nathan Landow Research Professorship. In 2009, Dr Khosla was voted President-Elect of The American Society for Bone and Mineral Research. William F. Young, Jr, MD, received the 2008 H. Jack Baskin, MD, Endocrine Teaching Award from the American Association of Clinical Endocrinologists.



Michael D. Jensen, MD, received the Tyson Family Endocrinology Clinical Professorship in Honor of Vahab Fatourehchi, MD. K. Sreekumaran Nair, MD, PhD, received an honorary Doctor of Medicine and Foreign Adjunct Professor at Karolinska Institute, Stockholm, Sweden, in May 2008.



Robert A. Rizza, MD, was inducted into the Johns Hopkins Society of Scholars in 2008. Richard F. Emslander, MD, received the Karis Award in 2008. The Karis Award formally recognizes the many caring persons at Mayo Clinic. Karis comes from the Greek word for "caring." At the November 20, 2008, Annual Staff Meeting election Michael D. Brennan, MD, was elected President of the Officers and Councilors, Mayo Clinic Rochester.

Mayo Clinic Endocrinology Update

Medical Editor:
William F. Young, Jr, MD, ELS

Editorial Board:
M. Regina Castro, MD
Bart L. Clarke, MD
Maria L. Collazo-Clavell, MD
Clive S. Grant, MD

Endocrinology Update is written for physicians and should be relied upon for medical education purposes only. It does not provide a complete overview of the topics covered and should not replace the independent judgment of a physician about the appropriateness or risks of a procedure for a given patient.

Contact Us

Referrals and Consultations

Arizona
866-629-6362

Florida
800-634-1417

Minnesota
800-533-1564

www.mayoclinic.org/medicalprofs

CME Opportunities

Mayo Clinic Nutrition in Health and Disease, September 24-25, 2009

Graves 601 Hotel, Minneapolis, Minnesota. This course, designed for physicians, dietitians, nurses, and pharmacists, will provide a full-spectrum, in-depth overview of challenging nutritional issues that clinicians encounter in the ambulatory and hospital settings. For more information about this course, please call 800-323-2688 or visit www.mayo.edu/cme/endocrinology.html.

13th Mayo Clinic Endocrine Course, July 14-17, 2010



Rochester, Minnesota. This course, created for endocrinologists and interested internists and surgeons, will present the latest material on the diagnosis and treatment of endocrine disorders.

Interested in receiving Mayo Clinic endocrinology news in your inbox?

Go to www.mayoclinic.org/medicalprofs to sign up for Mayo Clinic's new Physician Update – Endocrinology e-mail newsletter.



If you would like to be removed from the Mayo Clinic *Endocrinology Update* mailing list, please send an e-mail with your request to endocrineupdate@mayo.edu. However, please note this opt-out only applies to Mayo Clinic *Endocrinology Update*. You may continue to receive other mailings from Mayo Clinic in the future. Thank you.



4500 San Pablo Road
Jacksonville, FL 32224

200 First Street SW
Rochester, MN 55905

13400 East Shea Boulevard
Scottsdale, AZ 85259

MC5810-0209

www.mayoclinic.org

©2009 Mayo Foundation for Medical Education and Research (MFMER). All rights reserved. MAYO, MAYO CLINIC and the triple-shield Mayo logo are trademarks and service marks of FMFER.