

INSIDE THIS ISSUE

- 2 Discoveries in Neuromuscular Disease: Novel Subtypes of Myofibrillar Myopathy
- 4 Novel Microendoscopic Treatment for Spinal Dural Arteriovenous Fistulas
- 6 Minimally Invasive Surgery for Skull Base Tumors at Mayo Clinic in Florida

Schwannomatosis: A Newly Recognized Tumor-Predisposing Condition

The third annual Neurofibromatosis (NF) Forum, sponsored by the Children's Tumor Foundation, will be held in Minneapolis, Minnesota, on July 29 to 31, 2011. During the meeting, Mayo Clinic will host a breakout NF symposium in Rochester, Minnesota, for patients, families, and physicians. Speakers drawn from Mayo's numerous subspecialists with NF expertise (see sidebar) will discuss NF-related topics, including schwannomatosis.

Neurofibromatoses are complex hereditary conditions with highly variable presentation and severity. There are two major types: NF1 and NF2, the common feature of which is a predisposition toward multiple benign nerve sheath tumors. Recently, schwannomatosis has been recognized as an independent form of NF, distinct from NF2, which it resembles. The main clinical finding in schwannomatosis is the presence of benign neurogenic tumors in the absence of acoustic neuromas (vestibular schwannomas). In the past five years, schwannomatosis has been more clearly defined,

but it continues to be underrecognized and often misdiagnosed.

Distinguishing Schwannomatosis From NF2

The diagnostic criteria for schwannomatosis continue to evolve. Because the symptoms can be confused with NF2, it is critical that NF2 be ruled out during evaluation.

The key distinguishing features are the following:

- Cranial nerve involvement. Bilateral acoustic neuromas are the hallmark of NF2. They may occur simultaneously or sequentially. Patients with schwannomatosis may have schwannomas on other cranial nerves but do not have acoustic schwannomas.
- Segmental subtypes. In NF2 and schwannomatosis, tumors may occur in a random distribution, but in subtypes of both disorders, tumors can be segmental in distribution—localized to a single limb or in five or fewer contiguous spinal segments. Although segmental distribution occurs more often in schwannomatosis than in NF2, the pattern of tumor distribution is not necessarily helpful in differential diagnosis.
- Age of onset. NF2 usually affects young adults. In contrast, schwannomatosis typically occurs in the third to sixth decades of life.
- Inheritance. NF2 is an autosomal dominant syndrome caused by mutations in the NF2 gene, and genetic testing of blood and tissue is available for its detection. Schwannomatosis is usually sporadic, and familial cases occur in fewer than 20% of patients. A mutation in one tumor-suppressing gene (*INI1*) has been identified as a factor in a very small proportion of familial schwannomatosis cases. For the majority of patients, the genetic basis of schwannomatosis is not known.

To rule out NF2, a diagnosis of schwannomatosis is made in patients with multiple schwan-

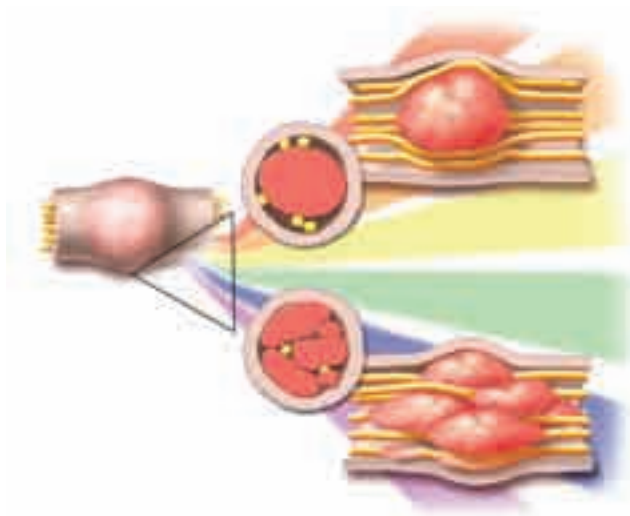



Figure. The spectrum of schwannomas in schwannomatosis: single fascicle (upper panel) to multinodular or plexiform (lower panel).

Subspecialties participating in the care of NF patients at Mayo Clinic in Rochester, Minnesota

- Audiology
- Dermatology
- Developmental Pediatrics
- Endocrinology
- Medical Genetics
- Neurology
- Neurosurgery
- Oncology
- Ophthalmology
- Orthopedic Surgery
- Otolaryngology
- Pain clinic
- Physical medicine and rehabilitation
- Plastic Surgery
- Psychology
- Radiology
- Social Services
- Speech Pathology

- nomas only in the following clinical situations:
- 1) High-resolution MRI demonstrates absence of acoustic nerve tumors in persons older than 30 years
 - 2) Genetic testing rules out the NF2 genes
 - 3) No first-degree relative has NF2



Robert J. Spinner, MD

Overcoming Diagnostic Challenges

Neural imaging can localize lesions suggestive of nerve tumor but cannot identify underlying pathology. A biopsy is required for definitive diagnosis, but nerve biopsy risks nerve damage. Robert

J. Spinner, MD, a neurosurgeon at Mayo Clinic in Rochester, Minnesota, who specializes in peripheral nerve surgery, points out that specialized techniques at Mayo Clinic can help determine the type and nature of peripheral nerve tumors while minimizing neurologic consequences.

Surgical Advances in Plexiform Schwannomas

Most schwannomas are encapsulated tumors that stem from a single, nonfunctional fascicle of a nerve which enters and exits the tumor (Figure). Typically, the tumor is in a small nonfunctional fascicle. In the hands of an experienced surgeon, resection of these conventional lesions using microsurgical techniques often has a favorable outcome.

However, not all schwannomas stem from a single fascicle. Some schwannomas may be multinodular or plexiform in nature, involving multiple nodules or fascicles, or both. In the majority of cases, plexiform schwannomas affect small nerves of the skin or subcutaneous tissue. But in some patients, plexiform tumors arise in major peripheral nerves. These more complex lesions have been identified in subgroups of patients with

schwannomatosis, in patients with NF2, and in those without a known syndrome.

Previously, plexiform schwannomas were thought to occur only in extreme cases, but Dr Spinner and his colleagues note that they also may occur in what were thought to be conventional lesions (Hébert-Blouin et al. *J Neurosurgery*. 2010;112[2]:372-82). High-resolution MRI can demonstrate the multifascicular involvement. These multinodular and plexiform tumors must be managed differently from conventional schwannomas and must be treated with special caution. Total resection of the lesion results in neurologic deficit due to the loss of more fascicles, many of which, despite the presence of tumor, are still functioning. In such cases, Dr Spinner and colleagues recommend a more conservative approach: observation in patients with minimal pain or a more limited resection of a painful dominant nodule.

Family-Based Research

Dr Spinner and Dusica Babovic-Vuksanovic, MD, a medical geneticist and the director of the Neurofibromatosis Clinic at Mayo Clinic in Rochester, Minnesota, are working together to create a registry of patients with schwannomatosis and their family members. Patient families have not yet been studied, and Drs Spinner and Babovic-Vuksanovic are including them to better understand the commonalities and variations in the disease. One question they hope to answer is whether there is a link between schwannomatosis and other tumor types. Their work in schwannomatosis is an example of Mayo's collaborative research and clinical commitment to patients with NF and other tumor-predisposing conditions.



Dusica Babovic-Vuksanovic, MD

Discoveries in Neuromuscular Disease: Novel Subtypes of Myofibrillar Myopathy

In 2008, Duygu Selcen, MD, a pediatric neurologist and research scientist at Mayo Clinic in Rochester, Minnesota, received a phone call from a pathologist at the University of Manitoba in Winnipeg, Canada. Marc R. Del Bigio, MD, wanted her input in determining the molecular

basis of a fatal muscle disease affecting Canadian Aboriginal infants of Cree ancestry. The children had rigid muscles and fatal respiratory insufficiency in infancy. Dr Del Bigio told her that the muscle biopsy specimens he had examined appeared to be like those found in a

type of muscular dystrophy called *myofibrillar myopathy* (MFM), even though the disease took a different course. All of the affected children died in infancy except one, who died at three years of age.

It is not surprising that Dr Del Bigio contacted Dr Selcen. The Muscle Research Laboratory at Mayo Clinic, established more than 40 years ago by her mentor, Andrew G. Engel, MD, receives more than 1,000 muscle biopsy specimens a year for histologic analysis. By the time Dr Selcen received the call, she and her colleagues had already made some important discoveries about the molecular basis and distinctions among types of MFM.

MFM encompasses a group of chronic, slowly progressive diseases of the skeletal muscle, the heart muscle, and the peripheral nerves. Symptoms can include weakness, paresthesias, peripheral neuropathy, muscle wasting, stiffness, aching, and cramps. In most patients, the disease presents in late adulthood, but a subtype of rapidly progressing MFM, identified by Dr Selcen and colleagues, can occur in childhood.

Tracking the Genes and Identifying New Subtypes

The term *myofibrillar myopathy* was coined 15 years ago, grouping together genetically heterogeneous neuromuscular disorders that previously were thought to be distinct but which share common morphologic characteristics. The common pathologic features include disorganization and degradation of the contractile filaments of striated muscle (myofibrils) originating at the Z disk.

The molecular abnormalities of MFM include the accumulation and aberrant expression of proteins. Only two of the genes had been identified until 2004, when Drs Selcen and Engel uncovered two more genes that cause MFM. Both of the newly identified genes were implicated in Z-disk structure and biology. The first gene, *myotilin*, helps to distinguish a subtype of MFM from the classic limb-girdle phenotype, highlighting the genetic heterogeneity of MFM and shedding new light on Z-disk mechanisms. The second gene, *ZASP*, defined a new form of MFM. *ZASP* is expressed more in cardiac than skeletal muscles and, prior to Dr Selcen's discovery, was known to cause only cardiomyopathy, not peripheral neuromuscular disease.

Discovery of Novel Pediatric MFM Subtype

More recently, Dr Selcen and colleagues discovered a mutation in yet another protein, a product of the *BAG-3* gene, which has antiapoptotic features. Their finding isolated a previously uniden-

tified severe, rapidly progressive, fatal childhood type of MFM. It marked the first time that *BAG-3*, typically associated with cancer, was implicated in human muscle disease. The finding is of immediate clinical significance because the symptoms of cardiomyopathy often occur before the disease shows up in the peripheral muscles. Affected children and adolescents may be candidates for heart transplantation, but if they have the *BAG-3* gene mutation, spine rigidity and respiratory failure will develop eventually, regardless of improved heart function. Now, under Dr Selcen's direction, the Mayo team is developing animal models to test antiapoptotic drugs in an effort to halt the progression of the disease.

MFM Subtype Unique to Canadian Aboriginals

What of the Canadian Aboriginal infants?

Dr Del Bigio was right: the muscle biopsy specimens shared multiple characteristics with MFM, particularly the abnormal accumulation of specific proteins. However, when Dr Selcen conducted further immunostaining tests, a protein that is always at increased levels in MFM was totally absent. Its absence provided the clue that led Drs Selcen and Del Bigio and their colleagues to pinpoint *CRYAB* as the disease gene—a discovery that will enable genetic testing, genetic counseling, and, eventually, disease prevention in this population.

Dr Selcen is both a clinician and a researcher. She routinely sees patients with MFM and other muscle diseases for clinical assessment and disease management. Her ongoing investigations at Mayo's Muscle Research Laboratory on malfunctioning genes and gene products in muscle disease have led to the identification of specific subtypes of childhood MFM, discoveries that have immediate management implications and hold the promise of identifying therapeutic interventions in the future.



Duygu Selcen, MD

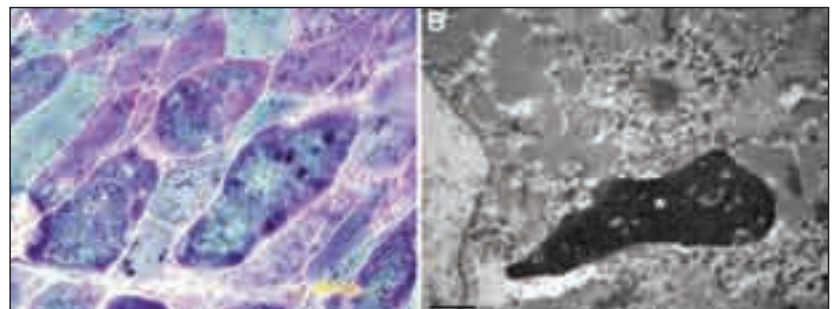


Figure. A. Trichrome stained section from a patient with *Bag3*opathy demonstrates abnormal inclusions in many muscle fibers. B. Electron micrograph of an abnormal muscle fiber shows an apoptotic nucleus (asterisk) and granular degradation products.

Novel Microendoscopic Treatment for Spinal Dural Arteriovenous Fistulas



Barry D. Birch, MD

Barry D. Birch, MD, and his neurosurgical colleagues at Mayo Clinic in Arizona are now performing a new, minimally invasive surgical approach for certain types of spinal dural arteriovenous fistulas (SDAVFs). Although rare, SDAVFs make up the majority of vascular malformations in the spine. An SDAVF is an abnormal connection (fistula) between one or more radicular arteries and a draining medullary vein at the junction of the proximal nerve root sleeve and the dura of the spine. SDAVFs can lead to pain and myelopathy.

As the medical center with the largest SDAVF practice in the United States, Mayo Clinic has a long tradition and a depth of experience with the disorder. John L. D. Atkinson, MD, a neurosurgeon at Mayo Clinic in Rochester, Minnesota, notes that patients often arrive in a deteriorating condition because their symptoms have been misinterpreted. SDAVFs often go underrecognized because the symptoms can be subtle and nonlocalizing and can be mistakenly attributed to coexisting abnormalities, such as lumbar stenosis, disk herniation, or vertebral anterolisthesis, that appear in imaging studies.

Treatment in which the fistula is disconnected can abruptly stop the deteriorating process and, if not too severely damaged, the spinal cord will regain function. Increased awareness in the medical community about the symptoms of SDAVFs will hopefully generate earlier referrals to centers with expertise in managing this disorder, leading to a better chance of recovery.

Last year, Mayo Clinic published the largest retrospective study ever conducted on the outcomes of patients with surgically treated SDAVFs (Saladino et al. *Neurosurgery*. 2010;67[5]:1350-8). On the basis of the series of 154 consecutive

patients, the authors concluded that surgical obliteration of SDAVFs is safe and effective, with a good prognosis for motor function recovery.

The mainstay of treatment, and the one used in the retrospective study, is an open surgical procedure. The approach requires a bilateral laminectomy one level above and one level below the fistula. Recovery times range from two days to more than a week—similar to those for a laminectomy for degenerative spine disease.

Recently, endovascular percutaneous embolization has been proposed as an alternate treatment for some SDAVFs. Embolization has the advantage of being less invasive with a shorter recovery time than open surgery, but recurrence rates are higher. In addition, embolization is not optimal for every patient. In some cases, angiography may reveal tortuous intradural vessels that are too difficult to navigate with a catheter. In other cases, the fistula may be so large that the embolization material could flow into the spinal column.

To manage such cases, Dr Birch and colleagues have been performing an innovative surgical technique that allows them to address SDAVFs with a microendoscopic approach (Figure). They have now used this approach in a series of patients with thoracolumbar fistulas involving single-vessel communication. All of the patients had gait instability; some also had bowel and bladder dysfunction and back pain. Ligation was successful, and no significant complications occurred during or after surgery. Hospital stays ranged from overnight to three days. Neurologic deficits were improved or stabilized in all patients, and follow-up imaging showed obliteration of the SDAVFs at the one-year follow-up visit.

As is true of other minimally invasive techniques, the small size of the incision in this new technique reduces the risk of infection following the procedure and minimizes the blood loss during it. Specialized experience is required to manage the fistula through such a small opening, but Dr Birch notes that “it means less pain for the patient and potentially less chance of spinal fluid leakage through the incision.” His neurosurgical colleague Naresh P. Patel, MD, adds that the microendoscopic approach appears to be a viable alternative for certain SDAVFs that cannot be treated endovascularly, providing the surgeon with an additional management strategy and enhancing individualized patient care.



Naresh P. Patel, MD

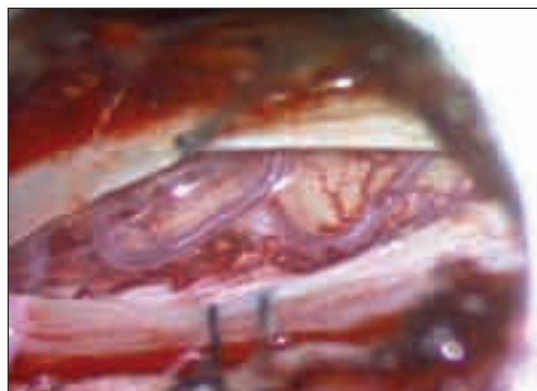


Figure. Dural arteriovenous fistula seen through a microendoscopic tubular retractor.

Research Highlights

Diet May Lower Risk of Cognitive Impairment

Mayo Clinic researchers found that the prevalence of mild cognitive impairment decreased with an increase in the consumption of monounsaturated and polyunsaturated fatty acids. As part of the Mayo Clinic Study of Aging, this research involved more than 1,200 participants who completed a 128-item food frequency questionnaire and reported their food intake within the past year. This study was published in the September 2010 issue of *Journal of Alzheimer's Disease*. Authors: R. Roberts, J. Cerhan, Y. Geda, D. Knopman, R. Cha, T. Christianson, V. Pankratz, R. Ivnik, H. O'Connor, and R. Petersen.

Predictors of Neurologic Outcome in Hypothermia After Cardiac Arrest

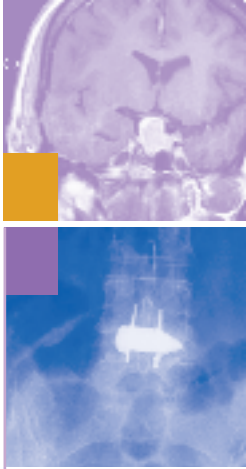
Mayo Clinic researchers determined that clinical examination (ie, brainstem reflexes, motor response, and presence of myoclonus) at day 3 after cardiac arrest continues to be an accurate predictor of outcome after therapeutic hypothermia. The effect of sedative medications in both hypothermic and normothermic patients may confound the clinical examination. Absence of pupillary light responses, corneal reflexes, and an extensor or absent motor response at day 3 still are accurate predictors of poor outcome after therapeutic hypothermia. The study was published in the December 2010 issue of *Annals of Neurology*. Authors: J. Fugate, E. Wijdicks, J. Mandrekar, D. Claassen, E. Manno, R. White, M. Bell, and A. Rabinstein.

WINCS Device Measures Serotonin Levels

A Mayo Clinic study concluded that through deep brain stimulation (DBS), a wireless instantaneous neurotransmitter concentration system (WINCS) can detect and measure serotonin levels in the brain. The findings suggest that in the future, such serotonin measurements may help establish a therapeutic mechanism of DBS for psychiatric disease. This study was published in the September 2010 issue of the *Journal of Neurosurgery*. Authors: C. Griessenauer, S. Chang, S. Tye, C. Kimble, P. Garris, and K. Lee.

Algorithm for the Genetic Testing of Frontotemporal Lobar Degeneration

Mayo Clinic researchers assisted in the development of a new algorithm for genetic testing of frontotemporal lobar degeneration. The algorithm was designed to allow clinicians to use clinical and neuroimaging phenotypes of the patient, along with family history and autopsy information, to decide whether genetic testing is warranted, and, if so, the order for appropriate tests in such cases. The study was published in the February 1, 2011, issue of *Neurology*. Authors: J. Goldman, R. Rademakers, E. Huey, A. Boxer, R. Mayeux, B. Miller, and B. Boeve.



• To read more about Mayo Clinic neurosciences research and patient care, visit www.mayoclinic.org.

Minimally Invasive Surgery for Skull Base Tumors at Mayo Clinic in Florida

Skull base tumors include meningiomas, pituitary tumors, clival chordomas, nasal tumors, chondrosarcomas, and craniopharyngiomas. Many skull base tumors involve the nose and nasal passages and compress the brain. A few years ago, most surgical resections for such tumors at Mayo Clinic involved a frontal craniotomy and lateral rhinotomy. Endoscopic approaches were available but were not often prescribed. Since then, a convergence of new technologies has made minimally invasive approaches safe and viable treatment alternatives for some tumors that can be approached through the nose and nasal passages, including large pituitary tumors (Figure). These technological advances have prompted an increase in minimally invasive techniques for skull base tumors across Mayo's three campuses.

At Mayo Clinic in Jacksonville, Florida, William E. Bolger, MD, an otorhinolaryngologist with special training in the endoscopic, minimally invasive approach to the nose and sinuses, has joined the interdisciplinary team caring for patients with skull base tumors. As he notes, "The advantage of these new approaches is that we get good exposure to the tumor without an external incision and facial trauma. Many tumors, such as meningiomas, that once required an open approach can sometimes be managed through an intrana-



William E. Bolger, MD, and Robert E. Wharen Jr, MD

sal endoscopic approach." His neurosurgical colleague Robert E. Wharen Jr, MD, adds that endoscopic techniques can reduce patient morbidity when used in appropriate situations. When warranted, minimally invasive approaches can often produce less discomfort and shorten hospital stays.

Several innovations available at Mayo Clinic have advanced minimally invasive skull base surgery. Image-guided surgery aids in tumor localization. Angled-view endoscopes can move with ease and flexibility through nasal passages while providing a wide-angle view of the tumor. Intraoperative MRI allows the surgeon to check for residual traces of the tumor during the procedure. Dr Bolger explains, "We use minimally invasive techniques most often to treat pituitary tumors, but we also use them to manage some benign bone tumors, encephaloceles, and other tumors, such as meningiomas."

These new technologies combined with specialized surgical techniques have enhanced individualized patient care. They provide another option for many patients with skull base tumors. But, as Drs Bolger and Wharen point out, each care plan at Mayo is based on patient needs—the patient's unique anatomy and the nature of the tumor. Dr Bolger adds that a "nonbiased approach based on these critical factors continues to be our guiding principle in managing skull base tumors."

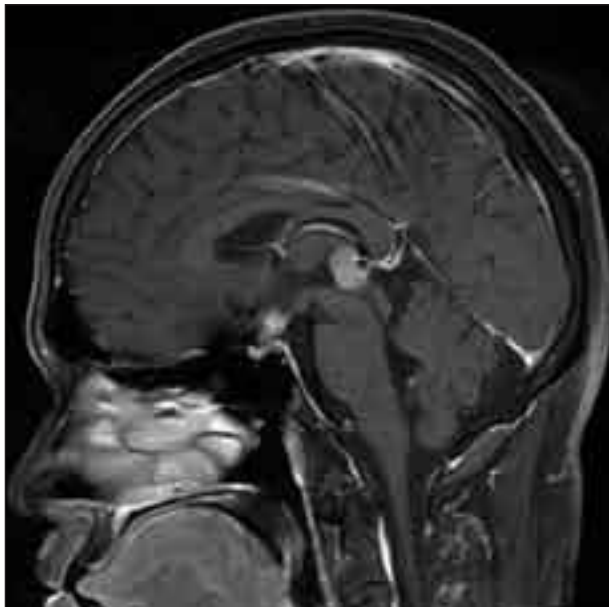


Figure. Sagittal MRI scan with increased signal intensity at the pituitary stalk. A transsphenoidal approach to the suprasellar cistern was performed, and biopsy revealed germinoma.

Mayo Clinic Neuroscientist Receives Potamkin Prize

Dennis Dickson, MD, was selected to receive the 2011 Potamkin Prize from the American Academy of Neurology (AAN). Dr Dickson is receiving the prize for his research involving Tau, a brain protein that is abnormal in a number of different neurodegenerative disorders, including Pick's disease and Alzheimer's disease. The Potamkin Prize for Research in Pick's, Alzheimer's, and Related Diseases honors researchers for their work in helping to advance the understanding of Alzheimer's disease and related disorders. The \$100,000 prize will be awarded at the AAN annual meeting in April and is to be used toward continuing dementia research and will be shared evenly between the three researchers.



Dennis Dickson, MD

H. Houston Merritt Award Given to Mayo Clinic Neurologist

Jasper Daube, MD, was selected to give the H. Houston Merritt Lecture at the American Academy of Neurology (AAN) annual meeting in April. The H. Houston Merritt Award and Lecture is awarded for excellence in clinically relevant research. The Merritt lecture is presented every other year during the Presidential Plenary Session of the Scientific Program of the AAN annual meeting.



Jasper Daube, MD

Mayo Clinic Neurologist Awarded John J. Dystel Prize

Brian Weinschenker, MD, was selected to receive the John J. Dystel Prize for Multiple Sclerosis Research from the American Academy of Neurology (AAN). It will be awarded at the Awards Plenary Session at the annual meeting of the AAN in April. The John J. Dystel Prize recognizes outstanding contributions to research in the understanding, treatment, or prevention of multiple sclerosis. The prize is intended to recognize significant and exciting work that has influenced the way we think about multiple sclerosis. The award is sponsored by AAN and the National Multiple Sclerosis Society.



Brian Weinschenker, MD

Mayo Clinic Neurosciences Update

Medical Editors:

Robert D. Brown Jr, MD
Robert J. Spinner, MD

Editorial Board:

Mark K. Lyons, MD
Ryan J. Uitti, MD

Science Writer:

Penelope S. Duffy, PhD

Neurosciences Update is written for physicians and should be relied upon for medical education purposes only. It does not provide a complete overview of the topics covered and should not replace the independent judgment of a physician about the appropriateness or risks of a procedure for a given patient.

Contact Us

You don't need to request a consult from a specific physician to refer a patient. We'll help you reach the most appropriate contact.

Arizona

866-629-6362

Florida

904-953-2103

Minnesota

Neurologic Consultation
507-284-1588

All Other Referrals
and Consultations

800-533-1564

www.mayoclinic.org/medicalprofs

Upcoming Conference

Mayo Headache Symposium

April 29-May 1, 2011

This course provides an update in the diagnosis and management of both primary and secondary headache disorders. The format includes lectures, expert panel discussions, interactive question and answer sessions, and small group discussions. The goals are to distinguish between primary headache disorders and headaches symptomatic of other diseases; to differentiate and accurately diagnose both episodic and chronic primary headache disorders; and to formulate treatment plans for primary headache disorders frequently encountered in both the primary care setting and general neurological practice.

Location: JW Marriott, 151 West Adams, Chicago, Illinois

Contact: 1-800-323-2688 or cme@mayo.edu

MAYO CLINIC		Physician Update Neurosciences	
March 2011	Regional News	Welcome to the first issue of Physician Update e-mail newsletter. This newsletter will offer access to articles from the Neurosciences print publication, plus other items of general interest to our physician audience.	
		Patient Care	
	Clinical Trials	Inpatient Video-EEG Monitoring for Epilepsy Continuous video-EEG monitoring (inpatient video-EEG) reduces focus, identifies seizure type, and quantifies the number of seizures in patients with intractable recurrent seizures and those with an unconfirmed seizure diagnosis.	
	Referring a Patient	Optimizing the Functional Performance of Cancer Survivors There is a growing understanding of the importance of exercise and rehabilitation for cancer survivors. Physical Medicine specialists can help patients manage the negative long-term sequelae of cancer and its treatments and obtain a more satisfying, high-quality recovery.	
		New Endoscopic Treatment for Severe Gastrointestinal Bleeding Endoscopic ultrasound-guided therapy appears to be a safe and effective treatment for patients with severe gastrointestinal bleeding for whom conventional therapies have failed. The therapy involves injecting various agents directly into the source to stop the bleeding.	
	Comments?	Less Can Be More When Treating Some Kidney Cancers A Mayo Clinic study suggests that removing less cancer tissue from younger patients	

Interested in receiving Mayo Clinic neurology and neurosurgery news in your inbox?

Go to www.mayoclinic.org/publications/medicalprofs-enews.html to sign up for Mayo Clinic's *Physician Update - Neurosciences* e-mail newsletter.

Expedited Patient Referrals to Mayo Clinic Departments of Neurology and Neurologic Surgery

While Mayo Clinic welcomes appointment requests for all neurologic and neurosurgical conditions, patients with the following conditions are offered expedited appointments:

1. Cerebral aneurysms
2. Cerebral or spinal arteriovenous malformations
3. Brain, spinal cord, or peripheral nerve tumors
4. Epilepsy with indications for surgery
5. Carotid disease

MAYO CLINIC | 4500 San Pablo Road | 200 First Street SW | 13400 East Shea Boulevard
mayoclinic.org | Jacksonville, FL 32224 | Rochester, MN 55905 | Scottsdale, AZ 85259

©2011 Mayo Foundation for Medical Education and Research. All rights reserved. MAYO, MAYO CLINIC and the triple-shield Mayo logo are trademarks and service marks of MFMER.

MC5520-0311